



## Neuroanatomy of Expressive Suppression: The Role of the Insula

Luma Muhtadie<sup>1</sup>, Claudia M. Haase<sup>2</sup>, Alice Verstaen<sup>1</sup>, Virginia E. Sturm<sup>3</sup>, Bruce L. Miller<sup>3</sup>, Robert W. Levenson<sup>1</sup>

<sup>1</sup>University of California, Berkeley

<sup>2</sup>Northwestern University

<sup>3</sup>University of California, San Francisco

### Abstract

Expressive suppression is a response-focused regulatory strategy aimed at concealing the outward expression of emotion that is already underway. Expressive suppression requires the integration of interoception, proprioception, and social awareness to guide behavior in alignment with personal and interpersonal goals—all processes known to involve the insular cortex. Frontotemporal dementia (FTD) provides a useful patient model for studying the insula's role in socioemotional regulation. The insula is a key target of early atrophy in FTD, causing patients to lose the ability to represent the salience of internal and external conditions, and to use these representations to guide behavior. We examined a sample of 59 patients with FTD, 52 patients with Alzheimer's disease (AD), and 38 neurologically healthy controls. Subjects viewed two disgust-eliciting films in the laboratory. During the first film, subjects were instructed to simply watch (emotional reactivity trial); during the second, they were instructed to hide their emotions (expressive suppression trial). Structural images from a subsample of participants (n=42; 11 FTD patients, 11 AD patients, and 20 controls) were examined in conjunction with behavior. FreeSurfer was used to quantify regional gray matter volume in 41 empirically derived neural regions in both hemispheres. Of the three groups studied, FTD patients showed the least expressive suppression and had the smallest insula volumes and, even after controlling for age, gender, and emotional reactivity. Among the brain regions examined, the insula was the only significant predictor of expressive suppression ability, with lower insula gray matter volume in both hemispheres predicting less expressive suppression.

### Keywords

insula; disgust; expressive suppression; neurodegenerative disease

---

Expressive suppression is a form of emotion regulation that involves conscious, voluntary inhibition of the outward manifestation of an ongoing emotional response (Gross, 2013; Gross & Levenson, 1993; Levenson, 1994). Although suppression is often viewed as a less adaptive emotion regulation strategy than cognitive reappraisal (Butler et al., 2003; Gross,

2002b; Haga, Kraft, & Corby, 2009; Moore, Zoellner, & Mollenholt, 2008), it has distinctive features that make it a highly useful strategy in certain contexts. For example, because cognitive reappraisal involves reinterpreting the meaning of a potential emotion-eliciting stimulus early in the elicitation process, expressive suppression may be the only viable regulation strategy later in the elicitation process when an emotion is already underway. Given that the primary function of expressive suppression is concealing rather than diminishing the underlying emotion (i.e., suppression does not appear to have an impact on the intensity of subjective emotional experience; Gross, 2002a; Gross & Levenson, 1993; Levenson, 1994), it is best viewed as a social regulation strategy. In the interest of maintaining harmonious relationships, we are often required to hide certain emotions to avoid their deleterious effect on others, even if this comes at a cost (e.g., increased sympathetic arousal; Gross, 2002a; Gross & Levenson, 1993; Levenson, 1994).

Another distinctive feature of expressive suppression is that it is a highly embodied strategy relying on the dynamic integration of interoceptive awareness (“What am I feeling right now?”), proprioceptive awareness (“Is this feeling showing on my face or body?”), social awareness (“Is it inappropriate or embarrassing to display this feeling here and now?”), and personal salience (“Are there risks or benefits of showing my emotions in this moment?”). When all of this information is combined in the service of expressive suppression, it produces dynamic behavior that is context-sensitive and adaptive.

Because expressive suppression is a response-focused strategy, aimed at concealing visible signs of emotion, and requiring interoceptive awareness, it would seem especially suited to emotions that arise quickly in response to significant threats. One such emotion is disgust, a highly visceral emotion arousing powerful affective and behavioral responses that evolved to protect against the threat of illness or contamination (Rozin, Haidt, & McCauley, 2008). When a person encounters certain unpleasant foods, objects, or smells, disgust and the attendant visceral sensations (nausea, gagging, etc.) are triggered almost instantly (Simpson, Carter, Anthony, & Overton, 2006), without requiring elaborate, protracted cognitive processing.

Recent evidence suggests that this phylogenetically older motivational system may in fact be co-opted during social transgressions or other cases of “bad taste.” For example, the facial motor actions and subjective feelings evoked by aversive chemical-sensory stimulation have been found to extend to other forms of disgust, including those related to cleanliness and contamination, and to be triggered when the everyday moral code of fairness is perceived to be violated (Chapman, Kim, Susskind, & Anderson, 2009). Further, because expressions of disgust can be interpreted as being directed toward the observer, or at least as unpleasant and non-affiliative (Fisher, Becker, & Veenstra, 2012), they often need to be suppressed in social contexts to maintain decorum. For example, a dinner party guest would likely offend her host by displaying disgust at his attire when he arrived at the door, or in response to an unfavorable entrée he placed in front of her at the dinner table. Indeed, many occupations, such as those involving caring for the ill or infirm, require individuals to suppress the expression of disgust if they are to perform their duties with professionalism and compassion (Curtis, 2011).

## The Putative Role of the Insula in Expressive Suppression

Because of the centrality of interoceptive awareness—the perception of signals originating in the body (Craig, 2002, 2003)—in expressive suppression, the insular cortex likely plays an important role in the brain circuitry associated with expressive suppression. Recent insights regarding the human insula’s connectivity and function suggest this region not only maps the state of the body, but that it does so in contextually relevant and emotionally significant ways (Craig, 2009, 2010; Critchley, 2005; Critchley, Mathias, & Dolan, 2001). The insula functions as a key hub within a neural network that subserves emotional salience processing (Beckmann, DeLuca, Devlin, & Smith, 2005; Seeley, Crawford, Zhou, Miller, & Greicius, 2009; Seeley et al., 2007). Primary interoceptive inputs from the body—such as sensations arising from the viscera and face—are first represented in the posterior insula. Then, beginning in an integrative zone in the mid-insula and proceeding in an anterior direction, the insula receives and combines inputs from multiple other limbic and cortical regions. Among these regions are the hypothalamus, which maintains homeostasis in the internal milieu; the nucleus accumbens, which processes the incentive motivational aspects of rewarding stimuli (Reynolds & Zahm, 2005; Robinson & Berridge, 2008); the amygdala, which is involved in emotional arousal, is critical for processing stimulus salience, and supports emotional learning and memory (Augustine, 1985; Jasmin, Burkey, Granato, & Ohara, 2004; Jasmin, Rabkin, Granato, Boudah, & Ohara, 2003; Paton, Belova, Morrison, & Salzman, 2006; Reynolds & Zahm, 2005); the anterior cingulate cortex, which engenders motivational aspects of emotion and is involved in various tasks related to self-monitoring and evaluating action selection (Augustine, 1996; Critchley, Tang, Glaser, Butterworth, & Dolan, 2005; Goldstein et al., 2007; Reynolds & Zahm, 2005; Rushworth & Behrens, 2008); and the orbitofrontal cortex, which is implicated in the context-dependent evaluation of environmental stimuli (Bechara, Damasio, & Damasio, 2000; Kringelbach, 2005; O’Doherty, Kringelbach, Hornak, Andrews, & Rolls, 2001; Ongür & Price, 2000; Ongür & Price, 2000; Rolls & Grabenhorst, 2008; Schoenbaum, Roesch, & Stalnaker, 2006; Schoenbaum, Setlow, Saddoris, & Gallagher, 2003). As this information gets integrated and re-represented in a posterior-to-anterior direction, it is abstracted to correspond more to one’s subjective feelings and motivations than to the objective features of the environment (Craig, 2010; Craig, Chen, Bandy, & Reiman, 2000). Ultimately, this process of integration, re-representation, and abstraction produces a coherent model of self that encompasses the state of the body, the social environment, and the person’s goals (Craig, 2002, 2009, 2010), thus providing the key representations thought to be necessary for expressive suppression.

## Research on the Neural Correlates of Expressive Suppression

There is not a great deal of research that has examined the neural correlates of expressive suppression. Existing studies of emotion regulation have tended to focus more on reappraisal than on suppression, and to link neural measures (both functional and structural) with self-reported regulation tendencies (e.g., Giuliani, Drabant, Bhatnagar, & Gross, 2011; Gross & John, 1997) rather than with performance-oriented measures of the *actual* regulation of emotional responses. Among studies using functional imaging and measuring actual expressive suppression: (a) suppressing emotional facial responses to negative visual images was associated with greater activation of bilateral insular cortex, supramarginal gyrus, and middle frontal gyrus activation compared to passive viewing (Hayes, et al., 2010); and (b)

suppressing disgust facial behavior to a disgust-eliciting film was associated with increased activation in the right amygdala and right insula throughout the film and in the right ventrolateral, dorsomedial, and dorsolateral prefrontal cortices late in the film (Goldin, McRae, Ramel, & Gross, 2008). In addition, a study in which participants were instructed to suppress subjective emotional experience to visual stimuli (Ohira et al., 2006) found activation of left prefrontal cortex, medial prefrontal cortex, and medial orbital prefrontal cortex including the rostral-ventral anterior cingulate cortex (Ohira et al., 2006).

To our knowledge, no study has used structural imaging to link regional gray matter volumes (in neurological patients or healthy controls) to a behavioral measure of emotion suppression or reappraisal.

### **Neurodegenerative Disease: A Window to the Insula's Role in Expressive Suppression**

Patients with neurodegenerative disease provide a useful model for studying the neuroanatomical correlates of emotional functioning. In these diseases, neural atrophy progresses along well defined neural networks with functional significance (Buckner et al., 2005; Seeley et al., 2009), providing a “lesion” model for studying brain-behavior relationships. One advantage of this approach is that behavioral assays can be conducted outside of the scanner environment, enabling emotional processes to be studied more naturalistically and without severe behavioral constraints (e.g., problems that emotion-related movement artifacts cause for functional imaging).

Patients with frontotemporal dementia (FTD) provide a particularly useful model for studying the role of the insula in emotion regulation. The major FTD clinical subtypes include behavioral variant, semantic dementia (SD), and progressive non-fluent aphasia (PNFA). Behavioral variant FTD (bvFTD) is associated with dramatic changes in social-emotional processing that result from focused medial frontal and fronto-insular degeneration (Seeley, 2010). SD presents with disintegration of word, object, person-specific, and emotional meaning (Hodges, Patterson, & Tyler, 1994; Seeley et al., 2005), followed by behavioral changes akin to those seen in bvFTD (Kertesz, McMonagle, Blair, Davidson, & Munoz, 2005; Seeley et al., 2005; Snowden et al., 2001), which result from degeneration beginning in the temporal pole and amygdala then spreading to subgenual cingulate, fronto-insular, ventral striatal, and upstream posterior temporal regions (Brambati et al., 2007). PNFA is associated with effortful, non-fluent, often agrammatic speech that is sometimes accompanied by speech apraxia or dysarthria and results from dominant frontal operculum and dorsal anterior insula injury (Gorno-Tempini et al., 2004; Josephs et al., 2006; Nestor et al., 2003).

In all three major subtypes of FTD, the insula is a key target of early atrophy (Rosen, Gorno-Tempini, Goldman, Perry, & Schuff, 2002), causing patients to lose the ability to represent the personal significance of internal and external events and to use these representations to guide behavior (Seeley, 2010). Consistent with the importance of these representations for emotion, prior research from our laboratory indicates that FTD patients show impairments in emotional reactivity and regulation. In terms of reactivity, we found that patients with behavioral variant FTD show reduced behavioral, physiological, and self-reported experiential responses to a disgusting film relative to controls (Eckart, Sturm, Miller, &

Levenson, 2012). In terms of regulation, we found that FTD patients generally show impairments in the ability to down-regulate emotional responses to an aversive acoustic startle stimulus relative to patients with Alzheimer's disease (AD) and neurologically normal controls (Goodkind, Gyurak, McCarthy, Miller, & Levenson, 2010).

Following up on this work using a sample of patients with FTD and other neurodegenerative diseases as well as neurologically healthy controls, we found that smaller insular volume was associated with reduced self-reported disgust and physiological activation in response to a disgusting film but not to a sad film (Verstaen et al., 2016). These findings regarding the role of the insula in emotional reactivity raise the question of whether insular and other neural region volumes are also associated with deficits in emotional suppression.

## The Present Study

The present study sought to examine the neuroanatomical basis of expressive suppression (i.e., downregulation of emotional behavior to a disgust-eliciting film) in patients with FTD, patients with AD, and age-matched neurologically healthy controls. As noted earlier, insular atrophy is common among patients with FTD (Seeley, 2010). Including patients with AD in our study increases anatomical and behavioral heterogeneity, as AD targets the medial temporal and parietal lobes (i.e., the default mode network) and typically manifests in memory, language, and visuospatial impairments (Levenson, Sturm, & Haase, 2014).

Three hypotheses were tested: (H1) patients with FTD will show less expressive suppression (more emotional behavior when instructed to hide their reactions to a disgust-eliciting film) than patients with AD and healthy controls; (H2) patients with FTD will have lower insula gray matter volumes than patients with AD and healthy controls; and (H3) across all participants, lower levels of insular gray matter volume will be associated with less expressive suppression.

## Method

### Participants

Participants were 59 patients diagnosed with FTD, 52 patients diagnosed with AD, and 38 cognitively normal, age-matched control participants. All participants were recruited through the Memory and Aging Center (MAC) at the University of California, San Francisco where they underwent an extensive multidisciplinary diagnostic and clinical evaluation (i.e., clinical interview, neurological examination, neuropsychological examination, structural magnetic resonance imaging [MRI]). FTD patients met standard diagnostic criteria (Neary, Snowden, Gustafson, Passant, & Stuss, 1998; Rascovsky et al., 2011) for behavioral variant FTD ( $n = 33$ ), semantic dementia ( $n = 17$ ), and progressive non-fluent aphasia ( $n = 9$ ) subtypes. AD patients met diagnostic criteria for Alzheimer's disease based on the National Institute of Neurological Disorders and Stroke criteria (McKhann et al., 1984). Control participants were screened to rule out any previous history of neurological or psychiatric disorder. See Table 1 for demographic and clinical characteristics of the three groups.

## Procedure

Participants came to the Berkeley Psychophysiology Laboratory for a daylong comprehensive assessment of emotional functioning (Levenson, 2007). Upon arriving, participants or their caregivers provided written informed consent for the laboratory procedures. Participants' upper torso and face were videotaped throughout the session using a high-resolution, partially concealed video camera. Stimuli were presented on a 21-inch video monitor placed directly in front of participants at a distance of 1.75m. At the end of the laboratory session, participants provided informed consent for subsequent use of the video recordings.

For the present study, we utilized data from two trials during which subjects viewed emotional films. Each trial began with a 60-second baseline period during which a large "X" was displayed on the monitor and participants were instructed to "watch the X". Participants were then given on-screen visual and verbal instructions for the upcoming film (see below). Participants viewed a 105-second film clip followed by a 30-second recovery period during which the screen was blank.

At the outset of the first trial, participants were instructed: "*In this next task, you will see a short film clip. Please try to relax and clear your mind until the film starts.*" They then viewed a 105-second excerpt from the television show "Fear Factor" in which a man sucks fluids from cow intestines and drinks a cup of this fluid. This first trial (reactivity trial) provided an assessment of emotional reactivity in the absence of explicit instructions to regulate emotion. At the outset of the second trial, participants were instructed: "*For the next task, you will watch another film. This time, **HIDE** your reaction so that no one would know how you feel while watching the film.*" They then viewed a 105-second excerpt from the movie "Pink Flamingos" in which a dog defecates and a person eats the dog feces. This second trial (expressive suppression trial) provided an assessment of ability to suppress behavioral responding to the film. Prior research has shown that both film clips are highly effective elicitors of disgust (Gross & Levenson, 1995; Gyurak, Goodkind, Kramer, Miller, & Levenson, 2012; Seider, Shiota, Whalen, & Levenson, 2011; Shiota & Levenson, 2012; Verstaen et al., 2016). All procedures were approved by, and in compliance with, the Institutional Review Board at the University of California.

## Measures

**Dementia severity.**—As part of the clinical assessment at the UCSF MAC, dementia severity was assessed using the Clinical Dementia Rating Scale (CDR; Morris, 1993). A total CDR score was obtained for each participant. Scores on this scale range from 0 to 3, with higher scores indicating greater functional impairment. Mean CDR scores and tests of group differences for FTD, AD, and Controls are reported in Table 1.

**Emotional behavior.**—Trained raters blind to diagnosis, trial, and study hypotheses viewed the video recordings without sound and coded emotional behaviors during the most intense 30-second period of each film clip as determined previously by a panel of raters. Using a modified version of the Emotional Expressive Behavior coding system (Gross & Levenson, 1993), 10 emotional behaviors were coded (amusement/happiness, anger,

confusion, contempt, disgust, embarrassment, fear, interest, sadness, and surprise) for each trial using an intensity scale ranging from 0 to 3 (0=none; 3=strong). Intercoder reliability for each trial, determined by having 2 to 4 coders rate 68% of the trials, was high (Cronbach's alpha = .91). For each emotion code, we summed the intensity scores for every occurrence of that emotion during the task and created a composite score for total emotional behavior by summing all 10 of the codes. Table 1 shows participants' total emotional behavior scores during the disgust reactivity and disgust suppression trials.

**Neuroimaging.**—Structural images from a subsample of 42 participants (11 patients with FTD, 8 right-handed; 11 patients with AD, 7 right-handed; and 20 healthy controls, 17 right-handed) were used in the brain-behavior analyses. Images for patient groups (FTD, AD) were only analyzed if the scan was completed within 3–4 months of the lab visit, and for healthy controls if the scan was completed within 12–14 months of the lab visit. A logistic regression analysis predicting whether participants were part of or not part of the neuroimaging sample showed that participants in the neuroimaging sample were statistically indistinguishable from the unscanned participants in terms of age, gender, CDR score, and emotional behavior during both the reactivity and expressive suppression trials, all  $ps > .338$ . There were proportionately fewer FTD patients,  $\text{Exp}(B) = .02$ ,  $p = .002$ , and fewer AD patients,  $\text{Exp}(B) = .02$ ,  $p = .002$ , than healthy controls in the neuroimaging sample than in the non-neuroimaging sample.

The structural scan and emotional assessment occurred in close temporal proximity to each other. Specifically, for participants with neurodegenerative disease, the mean period between the two sessions was  $M = .30$  months ( $SD = .48$ , range = 0–1) for FTD patients,  $M = 0.60$  months ( $SD = 1.34$ , range = 0–3) for AD patients. For healthy controls, the mean period between the two sessions was 1.93 months ( $SD = 2.40$ , range = 0–7).

Because the present study used data from participants recruited over a 3-year period (from 2007–2009) there were changes in magnet field strength. Most participants were tested using a 1.5T Siemens-CIND scanner ( $n = 25$ , 59.5% of scanned sample); 13 participants (31%) were tested using a 3T Siemens-NIC scanner; and 4 participants (9.5%) were tested using a 4T Siemens-CIND scanner.

**Brain volumes.**—Regional brain volumes were calculated using the FreeSurfer method. FreeSurfer is a semi-automated program that generates volumes for cortical and subcortical regions of interest (Desikan et al., 2006). This procedure has been shown to produce statistically indistinguishable results from those yielded by manual tracing (Fischl et al., 2002). For most participants ( $n = 33$ ), data were analyzed using FreeSurfer version 4.0.2; for a few participants, FreeSurfer versions 4.3.0 ( $n = 6$ ) and 4.5.0 ( $n = 3$ ) were used. New versions of FreeSurfer are released regularly to fix bugs and improve existing and/or add new tools (for detailed documentation of the different FreeSurfer versions, see “FreeSurfer Release Notes,” 2019). In terms of major changes, a noted issue with insula thickness computations was fixed in FreeSurfer version 4.0 (prior to all versions used in the present study). To account for possible differences between FreeSurfer versions, we included them as covariates in our statistical models (see below).

Because the neurodegenerative diseases in our sample may produce diffuse brain atrophy, we took a whole-brain approach and examined 41 cortical and subcortical regional volumes in both hemispheres (82 total) that were generated by FreeSurfer. These included: right and left insula, superior temporal sulcus, caudal anterior cingulate cortex, caudal middle frontal gyrus, cuneus, entorhinal cortex, frontal pole, fusiform gyrus, inferior parietal cortex, inferior temporal gyrus, isthmus of the cingulate gyrus, lateral occipital cortex, lateral orbitofrontal cortex, lingual gyrus, medial orbitofrontal cortex, middle temporal gyrus, paracentral lobule, parahippocampal gyrus, pars opercularis, pars orbitalis, pars triangularis, pericalcarine cortex, postcentral gyrus, posterior cingulate cortex, precentral gyrus, precuneus, rostral anterior cingulate cortex, rostral middle frontal gyrus, superior frontal gyrus, superior parietal cortex, supraorbital margin, superior temporal gyrus, temporal pole, transverse temporal cortex, thalamus, caudate, putamen, pallidum, hippocampus, amygdala, and accumbens area. A measure of total intracranial volume was also obtained and used as a covariate in analyses to control for head size. The FreeSurfer software authors request that the following explanatory paragraph be included in any study using this procedure:

Cortical reconstruction and volumetric segmentation was performed with the FreeSurfer image analysis suite, which is documented and freely available for download online (<http://surfer.nmr.mgh.harvard.edu/>). The technical details of these procedures are described in prior publications (Dale & Sereno, 2007; Desikan et al., 2006; Fischl, Liu, & Dale, 2001; Fischl et al., 2002; Fischl et al., 2004; Fischl, Sereno, & Dale, 1999; Fischl, Sereno, Tootell, & Dale, 1999; Han et al., 2006; Jovicich et al., 2006; Segonne et al., 2004). Briefly, this processing includes motion correction and averaging of multiple volumetric T1 weighted images (when more than one is available), removal of non-brain tissue using a hybrid watershed/surface deformation procedure (Segonne et al., 2004), automated Talairach transformation, segmentation of the subcortical white matter and deep gray matter volumetric structures (including hippocampus, amygdala, caudate, putamen, ventricles; Fischl et al., 2002; Fischl et al., 2004), intensity normalization (Sled, Zijdenbos, & Evans, 1998), tessellation of the gray matter white matter boundary, automated topology correction (Fischl et al., 2001; Segonne, Pacheco, & Fischl, 2007), and surface deformation following intensity gradients to optimally place the gray/white and gray/cerebrospinal fluid borders at the location where the greatest shift in intensity defines the transition to the other tissue class (Dale, Fischl, & Sereno, 1999; Dale & Sereno, 2007; Han et al., 2006). Once the cortical models are complete, a number of deformable procedures can be performed for in further data processing and analysis including surface inflation (Fischl, Sereno, & Dale, 1999), registration to a spherical atlas which utilized individual cortical folding patterns to match cortical geometry across subjects (Fischl, Sereno, Tootell, et al., 1999), parcellation of the cerebral cortex into units based on gyral and sulcal structure (Desikan et al., 2006; Fischl et al., 2004), and creation of a variety of surface based data including maps of curvature and sulcal depth. This method uses both intensity and continuity information from the entire three dimensional MR volume in segmentation and deformation procedures to produce representations of cortical thickness, calculated as the closest distance from the gray/white boundary to the gray/CSF boundary at each vertex on the tessellated surface (Han et al., 2006). The maps are created using spatial intensity gradients across tissue classes and are therefore not simply reliant on absolute signal intensity. The maps produced are not



restricted to the voxel resolution of the original data thus are capable of detecting submillimeter differences between groups. Procedures for the measurement of cortical thickness have been validated against histological analysis (Rosas et al., 2002) and manual measurements (Kuperberg et al., 2003; Salat et al., 2004). FreeSurfer morphometric procedures have been demonstrated to show good test-retest reliability across scanner manufacturers and across field strengths (Han et al., 2006).

### Statistical Analyses

To test our first hypothesis that patients with FTD will show less expressive suppression than patients with AD and healthy controls, we conducted a repeated-measures MANCOVA with total emotional behavior (10 behaviors) during the suppression trial as a within-subjects factor and diagnosis as a between-subjects factor. We also included gender as a between-subjects factor, and age and total emotional behaviors during the reactivity trial as covariates. Significant effects of diagnosis were followed up with simple contrasts.

To test our second hypothesis that patients with FTD will have lower bilateral insula gray matter volumes than patients with AD and healthy controls, we conducted a MANCOVA with left and right insula gray matter volume as the dependent variables and diagnosis as the between-subject factor. We also included gender, scanner type, and FreeSurfer version as between-subjects factors, and age and ICV as covariates.

To test our third hypothesis that lower levels of insula gray matter volume will be associated with less expressive suppression (i.e., greater emotional behavior when instructed to hide their reactions to the film) across all participants, we took a two-stage approach. First, based on prior studies of brain-behavior relationships (e.g., Sturm et al., 2013), we computed two-tailed partial bivariate correlations between total emotional behavior (i.e., composite of 10 emotional behavior codes) during the expressive suppression trial and all 41 regional brain volumes generated by FreeSurfer for each hemisphere (i.e., 82 total), controlling for (a) total emotional behavior during the reactivity trial (to account for any baseline differences in emotional reactivity); (b) total intracranial volume (ICV; total of gray matter, white matter, and cerebrospinal fluid volume, to control for any individual differences in brain size); (c) scanner type (3 dummy variables indicating 1.5T Siemens-CIND, 3T Siemens-CIND, and 4T Siemens-CIND, to control for differences in magnet strength); and (d) FreeSurfer version (2 dummy variables indicating FreeSurfer version 4.3.0 and 4.5.0). To allow for sufficient power to test our research question and following standard conventions designating  $r = .50$  as a large effect size (Cohen, 1992), only regions with large effect sizes ( $r_p > .50$ ; Cohen, 1992) were examined in the next stage, as in our previous work (Sturm et al., 2013). As described in detail below, this approach resulted in 19 regional brain volumes to be examined. Thus, next, we conducted stepwise hierarchical regression analyses with total emotional behavior (i.e., composite of 10 emotion behavior codes) during the expressive suppression trial as the dependent variable. To account for possible lateralization, we conducted two separate regressions for left and right hemisphere volumes. For both regressions, in Step 1, we included age and gender (to control for differences between the diagnostic groups) as well as total emotional behavior during the reactivity trial, ICV, scanner type, FreeSurfer version, and diagnosis (i.e., 2 dummy variables indicating AD and

FTD diagnosis, to rule out the possibility that significant findings were confined to one diagnostic group) as covariates. In Step 2, we used a forward-entry model to let the statistical program determine which brain region(s) accounted for significant variance in emotional behavior beyond the covariates. In follow-up analyses, we examined whether findings remained stable when applying Bonferroni corrections to account for multiple testing (for 19 regional brain volumes examined the corrected alpha was .0026). All analyses were conducted using SPSS Statistics for Macintosh, version 25 (IBM, 2017) .

## Results

Demographic, clinical, and emotional characteristics of patients with FTD, patients with AD, and Healthy Controls are presented in Table 1.

### Hypothesis 1. Neurodegenerative Disease and Expressive Suppression.

The repeated-measures MANCOVA revealed a marginally significant effect of diagnosis on emotional behavior during the suppression trial,  $F(2,134) = 4.69$ ,  $p = .011$ ,  $\eta_p = .07$ . Simple contrasts revealed that patients with FTD showed less expressive suppression (i.e., greater total emotional behavior during the suppression trial) than healthy controls,  $M_{diff} = .87$ ,  $SE(M_{diff}) = .29$ ,  $p = .003$ ; whereas patients with AD showed marginally less expressive suppression than patients with FTD ( $M_{diff} = .48$ ,  $SE(M_{diff}) = .26$ ,  $p = .064$ ) and were statistically indistinguishable from healthy controls  $M_{diff} = .39$ ,  $SE(M_{diff}) = .29$ ,  $p = .184$ ). Thus, our first hypothesis that patients with FTD would show less expressive suppression than the two comparison groups was supported for FTD patients versus healthy controls, but not for FTD versus AD (See Figure 1).

### Hypothesis 2. Neurodegenerative Disease and Insula Volume.

The MANCOVA revealed a significant effect of diagnosis on right insula gray matter volume,  $F(2,32) = 4.11$ ,  $p = .026$ ,  $\eta_p = .20$ , and left insula gray matter volume,  $F(2,32) = 4.12$ ,  $p = .026$ ,  $\eta_p = .21$ . Simple contrasts revealed that for the right hemisphere, patients with FTD had significantly lower right insula gray matter volumes than patients with AD,  $M_{diff} = -700.43$ ,  $SE(M_{diff}) = 332.87$ ,  $p = .043$ , and healthy controls,  $M_{diff} = -1019.90$ ,  $SE(M_{diff}) = 376.98$ ,  $p = .011$ . For the left hemisphere, patients with FTD had marginally lower left insula gray matter volumes than patients with ADs,  $M_{diff} = -677.10$ ,  $SE(M_{diff}) = 396.17$ ,  $p = .097$ , and significantly lower left insula gray matter volumes than healthy controls,  $M_{diff} = -1271.70$ ,  $SE(M_{diff}) = 447.48$ ,  $p = .008$ . Patients with AD did not differ from healthy controls in either right or left insula gray matter volumes,  $ps > .181$  (See Figure 2). Thus, for both hemispheres, our second hypothesis that patients with FTD would have lower insula gray matter volumes than patients with AD and healthy controls was supported, though the difference between FTD and AD patients was marginally significant for left hemisphere insula volume.

### Hypothesis 3. Insula Volume and Expressive Suppression.

**Preliminary analyses.**—The partial correlation analyses to determine which brain regions to include in our test of the association between brain volume and emotional behavior for each hemisphere revealed that 6 right-hemispheric brain regions and 13 left-

hemispheric brain regions correlated with total emotional behavior at our threshold level of  $r = 0.5$  or greater (for details on specific regions, see Table 2). Notably, the insula met this inclusion criterion for both hemispheres.

In the stepwise regression comparing the associations between the right hemisphere brain regions obtained from the partial correlation above (i.e., six candidate regions) and emotional behavior, only right insula volume was a significant predictor of emotional behavior. Specifically, lower right insula gray matter volume was associated with less expressive suppression (i.e., greater total emotional behavior during the expressive suppression trial),  $B = -.01$ ,  $SE(B) = .003$ ,  $\beta = -.63$ ,  $p < .001$ . In the stepwise regression comparing the associations between the left hemisphere brain regions obtained from the partial correlation above (i.e., 13 candidate regions) and emotional behavior, only left insula gray matter volume was a significant predictor of emotional behavior. Specifically, lower left insula gray matter volume was associated with less expressive suppression (i.e., greater total emotional behavior during the suppression trial),  $B = -.01$ ,  $SE(B) = .002$ ,  $\beta = -.66$ ,  $p < .001$  (See Figure 3). Thus, our third hypothesis that across all participants, lower insula gray matter volume would be associated with less expressive suppression in both hemispheres was supported. Findings remained stable when applying Bonferroni corrections to account for multiple testing.

## Discussion

We examined the relationship between neural loss and suppression of behavioral responses to a disgusting film in patients with FTD, patients with AD, and neurologically healthy controls. Our main findings were that (1) patients with FTD showed less expressive suppression than healthy controls, but not less than patients with AD; (2) patients with FTD had lower bilateral insula gray matter volume than both patients with AD and healthy controls; and (3) across all participants, lower insula gray matter volume was associated with less expressive suppression.

These findings suggest that the insula, a region typically associated with the generation of emotion (Adolphs, Tranel, & Damasio, 2003; Phillips, Drevets, Rauch, & Lane, 2003; Stein, Simmons, Feinstein, & Paulus, 2007; Verstaen et al., 2016; Wright, He, Shapira, Goodman, & Liu, 2004), is also involved in the regulation of emotion; specifically, expressive suppression. Indeed, among all the empirically derived neural regions we examined in both hemispheres, only insula gray matter volume was associated with expressive suppression ability; specifically, lower gray matter volume in both the right and left insula predicted less expressive suppression (i.e., greater emotional behavior when instructed to hide reactions to a disgust-eliciting film).

On the surface, an instruction to reduce visible signs of emotion seems simple. However, expressive suppression relies on the dynamic integration of a complex set of processes, including interoceptive and proprioceptive awareness, social awareness, and monitoring emotional salience in the service of personal and social goals. The present findings are consistent with a growing body of work suggesting that beyond its roles in viscerosensory awareness (Craig, 2002; Saper, 2002) and emotional responding (e.g., Adolphs et al., 2003;

Phillips et al., 2003; Stein et al., 2007; Verstaen et al., 2016; Wright et al., 2004), the insula plays a crucial role in integrating bottom-up sensory information with top-down regulatory signals in ways that serve adaptive motivated and social behavior (Berntson et al., 2011; Craig, 2009, 2010; Critchley, 2005, 2009; Damasio, 1999; Gu, Hof, Friston, & Fan, 2013; Seeley, 2010).

Our findings are particularly informative in helping to understand the neural basis of a prominent behavioral problem seen in patients with FTD. Anatomical studies have revealed insular atrophy early in the course of FTD (Seeley, 2008, 2010). Behavioral research has indicated that patients with FTD exhibit deficits in expressive suppression (Goodkind et al., 2010). The present study confirms both of these findings and goes on to establish a direct link between lower insula volume and diminished expressive suppression ability.

Results of tests of our first hypothesis—that patients with FTD would have diminished expressive suppression ability compared to healthy controls (i.e., more emotional behavior when explicitly instructed to hide their reactions to a disgust-eliciting film)—corroborates one of the hallmark features of FTD observed in clinical and real-world settings: disinhibited social behavior. Early in the disease process, patients with FTD often behave in ways that violate social norms (e.g., making offensive remarks, encroaching on the personal space of others, exhibiting lack of etiquette; Manoochehri & Huey, 2012). Although we focused on a very specific emotion regulation skill, instructed expressive suppression, the diminished ability we found in patients with FTD to inhibit a dominant response (i.e., the behavioral display of emotion) and to coordinate/execute a subdominant response (i.e., to conceal any felt emotions in accordance with task instructions) dovetails with the broader difficulties these patients are known to have with judgment, loss of initiative, deficient self-control, compulsive or stereotypic behavior, and loss of interpersonal caring and tact (Miller, Chang, Mena, Boone, & Lesser, 1993; Snowden et al., 2001). Notably, patients with FTD did not differ significantly from patients with AD in expressive suppression ability. This may be due to the general cognitive complexity of the task instructions and demands for patients with AD, rather than to expressive suppression per se; however, our data do not enable us to establish this conclusively. Nonetheless, the overall pattern of findings was graded, with the FTD group showing the least expressive suppression, followed in turn by the AD group and healthy controls. Thus, with greater statistical power, the difference between FTD and AD groups may have reached statistical significance.

Results of tests of our second hypothesis—that patients with FTD would have lower bilateral insula gray matter volumes than both patients with AD and healthy controls—align with the distinctive structural and functional features of FTD versus those of AD. In terms of the three clinical subtypes of FTD, studies reveal that behavioral variant FTD involves the ventral and dorsal anterior insula early in the disease (Seeley, 2008); semantic dementia begins with the left or right temporal pole, but later spreads to ventral anterior insula (Pereira et al., 2009; Rohrer et al., 2009); and progressive non-fluent aphasia primarily involves degeneration of dorsal anterior insula (Gorno-Tempini et al., 2004; Nestor et al., 2003; Rohrer et al., 2009). By contrast, AD is characterized neuroanatomically by cortical atrophy in the medial temporal and parietal lobes (Seeley et al., 2009; Seeley et al., 2007) and

clinically by cognitive impairments (i.e., episodic memory, language, and visuospatial dysfunction), with socio-emotional functioning remaining relatively spared.

Finally, results of tests of our third hypothesis—that lower insula volume would be associated with diminished expressive suppression ability—allowed us to link structure and function directly. The human ventral frontoinsula responds to diverse visceral and autonomic challenges and co-activates with the amygdala and anterior cingulate cortex during a range of social-emotional paradigms (Critchley, 2005; Kurth, Zilles, Fox, Laird, & Eickhoff, 2010; Mutschler et al., 2009; Singer, Critchley, & Preuschoff, 2009). The functions of the dorsal anterior insula are less clear, but data suggest it plays a role in response suppression, task switching, and task maintenance (Aron, Robbins, & Poldrack, 2004; Dosenbach et al., 2006). In linking structure and function directly, the present study corroborates previous research implicating the insula in expressive suppression (Giuliani et al., 2011; Goldin, McRae, Ramel, & Gross, 2008), and builds on it further by assessing the structural correlates of actual expressive suppression and by doing so in a sample of neurological patients.

### Questions for Future Research

The present study raises important questions as to the boundary conditions of the present findings, including whether they extend to: (a) stimuli other than disgust-eliciting ones, (b) forms of emotion regulation other than expressive suppression (e.g., reappraisal, attentional control), (c) the *up*regulation of emotion (i.e., displaying exaggerated responses when these are socially appropriate), and (d) suppression of other aspects of the emotional response package (i.e., physiology and subjective experience). Because we view the accurate representation and processing of bodily information as critical to all types of emotion regulation, we would expect the insula to be important across these aforementioned conditions. Nonetheless, interesting differences might also emerge; for example, when regulating emotions that are arguably less visceral than disgust (e.g., sadness) or when bodily responses are not the targets of behavioral modulation (i.e., regulation via reappraisal or attentional control as opposed to expressive suppression).

In addition, structural parcellation in this study was limited to the left and right insula and did not examine the insula's posterior/anterior or dorsal/ventral divisions, each of which has functional specificity. Whereas the posterior and mid-insula share projections with the somatosensory cortex and receive visceral afferent projections that convey interoceptive information about bodily states (Craig, 2002), the anterior insula is highly connected with limbic (e.g. amygdala, ventral striatum) and prefrontal cortical (e.g., anterior cingulate cortex, orbitofrontal cortex) structures (Mesulam & Mufson, 1982; Öngür & Price, 2000). Accordingly, information is represented in its simplest form in the posterior and mid-insula and in a more abstracted, contextualized form in the anterior insula. In terms of dorsal/ventral subregions, the dorsal insula is chiefly involved in representing visceral and somatosensory information, whereas the ventral insula appears to be more important for integrating interoceptive signals with information pertaining to salience, focal attention, and the emotional modulation of autonomic activity (Simmons et al., 2013). It would thus be interesting in future work to explore the relative contributions of these subregions to various emotional reactivity and regulation processes.

## Strengths and Limitations

Strengths of the present study include its relatively large sample size (for patient research); inclusion of patients with multiple neurological disorders; quantitative analysis of brain volumes from structural brain images; and objective coding of emotional behaviors during emotion regulation in a relatively naturalistic context. Limitations include focusing on a single emotional elicitor (disgust); examining a single regulatory strategy (expressive suppression); lack of precision in the anatomical analyses (e.g., not being able to quantify insula subregions); the small sample for the neuroimaging analyses (with different cell sizes for the different diagnostic groups); and use of different scanners with different magnet strengths. We hope to address these limitations in future work.

## Conclusion

We found evidence that patients with FTD show greater deficits in expressive suppression than healthy controls; greater loss of bilateral insular gray matter volume than both patients with AD and healthy controls; and that across the neurologically heterogeneous sample, greater insular volume loss was associated with more profound deficits in expressive suppression. This research contributes to a growing body of literature highlighting the insula's role in emotion and provides new information concerning the important role the insula plays in emotion regulation specifically. In addition, the links between insular loss and deficits in expressive suppression appear to explain some of the hallmark social and emotional changes observed in patients with FTD.

## Acknowledgments

This research was supported by a National Institute of Aging Grant 2P01AG019724-11 to Robert W. Levenson and a National Institute of Aging Grant 1R01AG041762-01A1 to Robert W. Levenson.

## References

- Adolphs R, Tranel D, & Damasio AR (2003). Dissociable neural systems for recognizing emotions. *Brain and Cognition*, 52, 61–69. doi:[10.1016/S0278-2626\(03\)00009-5](https://doi.org/10.1016/S0278-2626(03)00009-5)
- Aron AR, Robbins TW, & Poldrack RA (2004). Inhibition and the right inferior frontal cortex. *Trends in Cognitive Sciences*, 8, 170–177. doi:[10.1016/j.tics.2004.02.010](https://doi.org/10.1016/j.tics.2004.02.010)
- Augustine JR (1985). The insular lobe in primates including humans. *Neurological Research*, 7, 2–10.
- Augustine JR (1996). Circuitry and functional aspects of the insular lobe in primates including humans. *Brain Research Reviews*, 22, 229–244. doi:[10.1016/S0165-0173\(96\)00011-2](https://doi.org/10.1016/S0165-0173(96)00011-2)
- Bechara A, Damasio H, & Damasio AR (2000). Emotion, decision making and the orbitofrontal cortex. *Cerebral Cortex*, 10, 295–307. doi:[10.1093/cercor/10.3.295](https://doi.org/10.1093/cercor/10.3.295)
- Beckmann CF, DeLuca M, Devlin JT, & Smith SM (2005). Investigations into resting-state connectivity using independent component analysis. *Philosophical Transactions of the Royal Society of London. Series B, Biological Sciences*, 360, 1001–1013. doi :[10.1098/rstb.2005.1634](https://doi.org/10.1098/rstb.2005.1634)
- Berntson GG, Norman GJ, Bechara A, Tranel D, Bruss J, & Cacioppo JT (2011). The insula, the amygdala and evaluative processes. *Psychological Science*, 22, 80–86. doi: [10.1177/0956797610391097](https://doi.org/10.1177/0956797610391097)
- Brambati SM, Rankin KP, Narvid J, Seeley WW, Dean D, Rosen HJ, ... Gorno-Tempini ML (2007). Atrophy progression in semantic dementia with asymmetric temporal involvement: a tensor-based morphometry study. *Neurobiological Aging*, 30, 103–111. doi: [10.1016/j.neurobiolaging.2007.05.014](https://doi.org/10.1016/j.neurobiolaging.2007.05.014)

- Buckner RL, Snyder AZ, Shannon BJ, LaRossa G, Sachs R, Fotenos AF, ... Mintun MA (2005). Molecular, structural, and functional characterization of Alzheimer's disease: evidence for a relationship between default activity, amyloid, and memory. *Journal of Neuroscience*, 25, 7709–7717. doi:[10.1523/JNEUROSCI.2177-05.2005](https://doi.org/10.1523/JNEUROSCI.2177-05.2005)
- Butler EA, Egloff B, Wilhelm FH, Smith NC, Erickson EA, & Gross JJ (2003). The social consequences of expressive suppression. *Emotion*, 3, 48–67. doi:[10.1037/1528-3542.3.1.48](https://doi.org/10.1037/1528-3542.3.1.48)
- Chapman HA, Kim DA, Susskind JM, & Anderson AK (2009). In bad taste: evidence for the oral origins of moral disgust. *Science*, 323, 1222–1226. doi:[10.1126/science.1165565](https://doi.org/10.1126/science.1165565)
- Cohen J. (1992). A power primer. *Psychological Bulletin*, 112, 155–159. doi:[10.1037/0033-2909.112.1.155](https://doi.org/10.1037/0033-2909.112.1.155)
- Craig AD (2002). How do you feel? Interoception: the sense of the physiological condition of the body. *Nature Reviews Neuroscience*, 3, 655–666. doi:[10.1038/nrn894](https://doi.org/10.1038/nrn894)
- Craig AD (2003). Interoception: The sense of the physiological condition of the body *Current Opinion in Neurobiology*, 13, 500–505. doi:[10.1016/S0959-4388\(03\)00090-4](https://doi.org/10.1016/S0959-4388(03)00090-4)
- Craig AD (2009). How do you feel — now? The anterior insula and human awareness. *Nature Reviews Neuroscience*, 10, 59–70. doi:[10.1038/nrn2555](https://doi.org/10.1038/nrn2555)
- Craig AD (2010). The sentient self. *Brain Structure & Function*, 214, 563–577. doi: [10.1007/s00429-010-0248-y](https://doi.org/10.1007/s00429-010-0248-y)
- Craig AD, Chen K, Bandy D, & Reiman EM (2000). Thermosensory activation of insular cortex. *Nature Neuroscience*, 3, 184–190. doi:[10.1038/72131](https://doi.org/10.1038/72131)
- Critchley HD (2005). Neural mechanisms of autonomic, affective, and cognitive integration. *Journal of Comparative Neurology*, 493, 154–166. doi:[10.1002/cne.20749](https://doi.org/10.1002/cne.20749)
- Critchley HD (2009). Psychophysiology of neural, cognitive and affective integration: fMRI and autonomic indicants. *International Journal of Psychophysiology*, 73, 88–94. doi:[10.1016/j.ijpsycho.2009.01.012](https://doi.org/10.1016/j.ijpsycho.2009.01.012)
- Critchley HD, Mathias CJ, & Dolan RJ (2001). Neuroanatomical basis for first- and second-order representations of bodily states. *Nature Neuroscience*, 4, 207–212. doi: [10.1038/84048](https://doi.org/10.1038/84048)
- Critchley HD, Tang J, Glaser D, Butterworth B, & Dolan RJ (2005). Anterior cingulate activity during error and autonomic response. *NeuroImage*, 27, 885–895. doi:[10.1016/j.neuroimage.2005.05.047](https://doi.org/10.1016/j.neuroimage.2005.05.047)
- Curtis V. (2011). Why disgust matters. *Philosophical Transactions of the Royal Society of London. Series B, Biological Sciences*, 366, 3478–3490. doi:[10.1098/rstb.2011.0165](https://doi.org/10.1098/rstb.2011.0165)
- Dale AM, Fischl B, & Sereno MI (1999). Cortical surface-based analysis. I: segmentation and surface reconstruction. *NeuroImage*, 9, 179–194. doi:[10.1006/nimg.1998.0395](https://doi.org/10.1006/nimg.1998.0395)
- Dale AM, & Sereno MI (2007). Improved localizadon of cortical activity by combining EEG and MEG with MRI cortical surface reconstruction: a linear approach. *Journal of Cognitive Neuroscience*, 5, 162–176. doi:[10.1162/jocn.1993.5.2.162](https://doi.org/10.1162/jocn.1993.5.2.162)
- Damasio AR (1999). *The feeling of what happens: body and emotion in the making of consciousness*. Orlando, FL: Harcourt.
- Desikan RS, Segonne F, Fischl B, Quinn BT, Dickerson BC, Blacker D, ... Killiany RJ (2006). An automated labelling system for subdividing the human cerebral cortex on MRI scans into gyral based regions of interest. *NeuroImage*, 31, 968–980. doi:[10.1016/j.neuroimage.2006.01.021](https://doi.org/10.1016/j.neuroimage.2006.01.021)
- Dosenbach NU, Visscher KM, Palmer ED, Miezin FM, Wenger KK, Kang HC, ... Petersen SE (2006). A core system for the implementation of task sets. *Neuron*, 50, 799–812. doi :[10.1016/j.neuron.2006.04.031](https://doi.org/10.1016/j.neuron.2006.04.031)
- Eckart JA, Sturm VE, Miller BL, & Levenson RW (2012). Diminished disgust reactivity in behavioral variant frontotemporal dementia. *Neuropsychologia*, 50, 786–790. doi:[10.1016/j.neuropsychologia.2012.01.012](https://doi.org/10.1016/j.neuropsychologia.2012.01.012)
- Fischl B, Liu A, & Dale AM (2001). utomated manifold surgery: constructing geometrically accurate and topologically correct models of the human cerebral cortex. *IEEE Transactions on Medical Imaging*, 20, 70–80. doi:[10.1109/42.906426](https://doi.org/10.1109/42.906426)
- Fischl B, Salat DH, Busa E, Albert M, Dieterich M, Hasselgrove C, ... Dale AM (2002). Whole brain segmentation: automated labeling of neuroanatomical structures in the human brain. *Neuron*, 33, 341–355. doi:[10.1016/S0896-6273\(02\)00569-X](https://doi.org/10.1016/S0896-6273(02)00569-X)

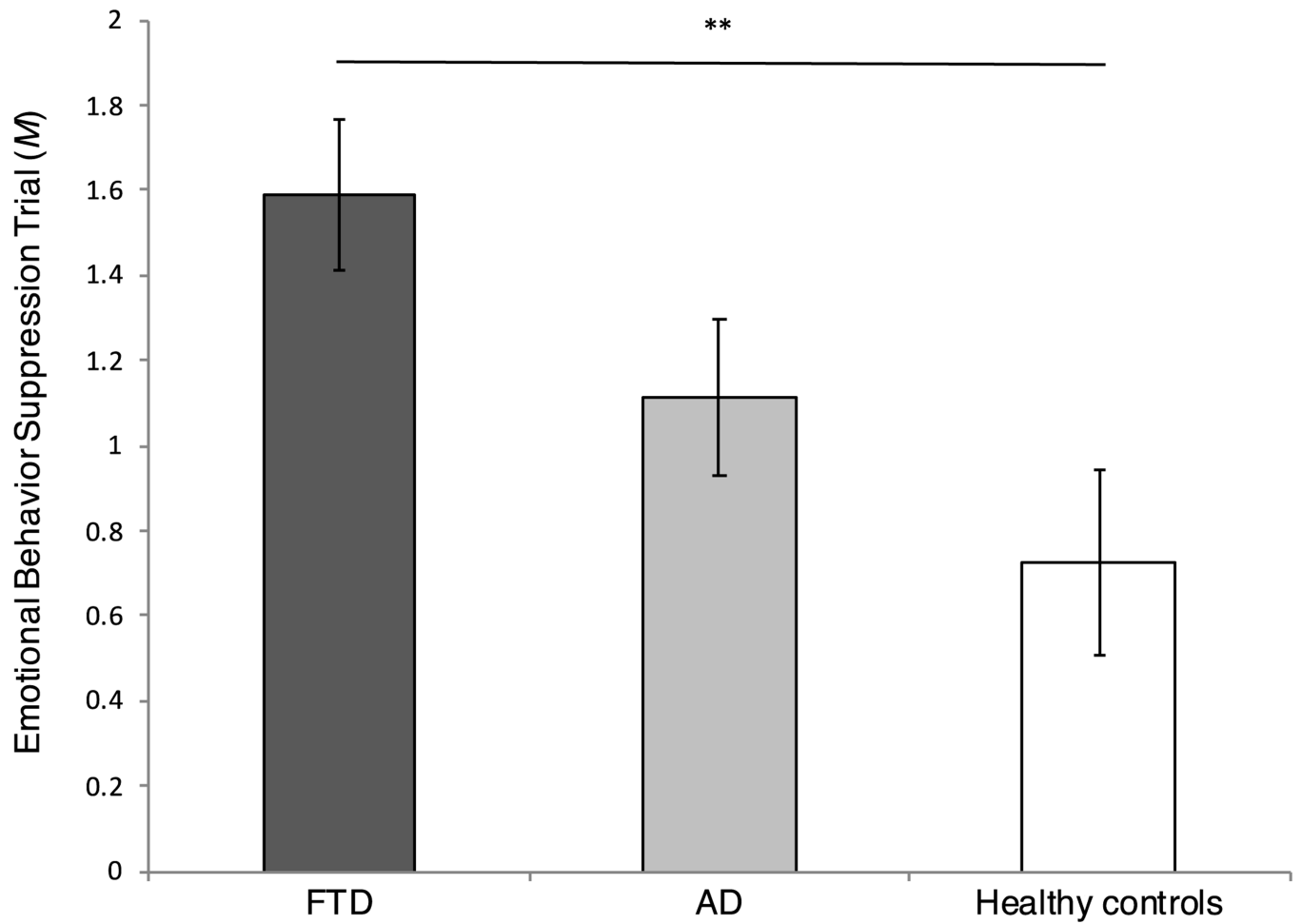
- Fischl B, Salat DH, van der Kouwe AJ, Makris N, Ségonne F, Quinn BT, & Dale AM (2004). Sequence-independent segmentation of magnetic resonance images. *NeuroImage*, 23, S69–S84. doi:[10.1016/j.neuroimage.2004.07.016](https://doi.org/10.1016/j.neuroimage.2004.07.016)
- Fischl B, Sereno MI, & Dale AM (1999). Cortical surface-based analysis. II: inflation, flattening, and a surface-based coordinate system. *NeuroImage*, 9, 195–207. doi: [10.1006/nimg.1998.0396](https://doi.org/10.1006/nimg.1998.0396)
- Fischl B, Sereno MI, Tootell RB, & Dale AM (1999). High-resolution intersubject averaging and a coordinate system for the cortical surface. *Human Brain Mapping*, 8, 272–284.
- Fisher AH, Becker D, & Veenstra L. (2012). Emotional mimicry in social context: the case of disgust and pride. *Frontiers in Psychology*, 3. doi:[10.3389/fpsyg.2012.00475](https://doi.org/10.3389/fpsyg.2012.00475)
- FreeSurfer Release Notes. (2019). FreeSurfer Wiki. Retrieved September 7, 2019 from <http://surfer.nmr.mgh.harvard.edu/fswiki/ReleaseNotes>
- Giuliani NR, Drabant EM, Bhatnagar R, & Gross JJ (2011). Emotion regulation and brain plasticity: Expressive suppression use predicts anterior insula volume. *NeuroImage*, 58, 10–15. doi:[10.1016/j.neuroimage.2011.06.028](https://doi.org/10.1016/j.neuroimage.2011.06.028)
- Goldin PR, McRae K, Ramel W, & Gross JJ (2008). The neural bases of emotion regulation: Reappraisal and suppression of negative emotion. 63, 577–586. doi : [10.1016/j.biopsycho.2007.05.031](https://doi.org/10.1016/j.biopsycho.2007.05.031)
- Goldstein RZ, Tomasi D, Rajaram S, Cottone LA, Zhang L, Maloney T, ... Volkow ND (2007). Role of the anterior cingulate and medial orbitofrontal cortex in processing drug cues in cocaine addiction. *Neuroscience*, 144, 1153–1159. doi :[10.1016/j.neuroscience.2006.11.024](https://doi.org/10.1016/j.neuroscience.2006.11.024)
- Goodkind MS, Gyurak A, McCarthy M, Miller BL, & Levenson RW (2010). Emotion regulation deficits in frontotemporal lobar degeneration and Alzheimer’s Disease. *Psychology of Aging*, 25, 30–37. doi:[10.1037/a0018519](https://doi.org/10.1037/a0018519)
- Gorno-Tempini ML, Dronkers NF, Rankin KP, Ogar JM, Phengrasamy L, Rosen HJ, ... Miller BL (2004). Cognition and anatomy in three variants of primary progressive aphasia. *Annals of Neurology*, 55, 335–346. doi:[10.1002/ana.10825](https://doi.org/10.1002/ana.10825)
- Gross JJ (2002a). Emotion regulation: affective, cognitive, and social consequences. *Psychophysiology*, 39, 281–291. doi:[10.1017.S0048577201393198](https://doi.org/10.1017/S0048577201393198)
- Gross JJ (2002b). Emotion regulation: Affective, cognitive, and social consequences. *Psychophysiology*, 39, 281–291. doi:[10.1017/S0048577201393198](https://doi.org/10.1017/S0048577201393198)
- Gross JJ (2013). *Handbook of emotion regulation* (2 ed.). New York, NY: Guilford Press.
- Gross JJ, & John OP (1997). Revealing feelings: Facets of emotional expressivity in self-reports, peer ratings, and behavior. *Journal of Personality & Social Psychology*, 72(2), 435–448.
- Gross JJ, & Levenson RW (1993). Emotional suppression: physiology, self-report, and expressive behavior. *Journal of Personality and Social Psychology*, 64, 970–986. doi: [10.1037//0022-3514.64.6.970](https://doi.org/10.1037//0022-3514.64.6.970)
- Gross JJ, & Levenson RW (1995). Emotion elicitation using films. *Cognition and Emotion*, 9, 87–108. doi:[10.1080/02699939508408966](https://doi.org/10.1080/02699939508408966)
- Gu X, Hof PR, Friston KJ, & Fan J. (2013). Anterior insular cortex and emotional awareness. *Journal of Comparative Neurology*, 521, 3371–3388. doi:[10.1002/cne.23368](https://doi.org/10.1002/cne.23368)
- Gyurak A, Goodkind MS, Kramer JH, Miller BL, & Levenson RW (2012). Executive functions and the down-regulation and up-regulation of emotion. *Cognition and Emotion*, 26, 103–118. doi: [10.1080/02699931.2011.557291](https://doi.org/10.1080/02699931.2011.557291)
- Haga SM, Kraft P, & Corby E. (2009). Emotion regulation: antecedents and well-being outcomes of cognitive reappraisal and expressive suppression in cross-cultural samples. *Journal of Happiness Studies*, 10, 271–291. doi:[10.1007/s10902-007-9080-3](https://doi.org/10.1007/s10902-007-9080-3)
- Han X, Jovicich J, Salat D, van der Kouwe A, Quinn BT, Czanner S, ... Fischl B. (2006). Reliability of MRI-derived measurements of human cerebral cortical thickness: the effects of field strength, scanner upgrade and manufacturer. *Neuroimage*, 32, 180–194. doi:[10.1016/j.neuroimage.2006.02.051](https://doi.org/10.1016/j.neuroimage.2006.02.051)
- Hodges JR, Patterson K, & Tyler LK (1994). Loss of semantic memory: implications for the modularity of mind. *Cognitive Neuropsychology*, 11, 505–542.
- IBM. (2017). SPSS Statistics for Macintosh, version 25. IBM Corp, Armonk, NY, USA.



- Jasmin L, Burkey AR, Granato A, & Ohara PT (2004). Rostral agranular insular cortex and pain areas of the central nervous system: a tract-tracing study in the rat. *Journal of Comparative Neurology*, 468, 425–440. doi:[10.1002/cne.10978](https://doi.org/10.1002/cne.10978)
- Jasmin L, Rabkin SD, Granato A, Boudah A, & Ohara PT (2003). Analgesia and hyperalgesia from GABA-mediated modulation of the cerebral cortex. *Nature*, 424, 316–320. doi:[10.1038/nature01808](https://doi.org/10.1038/nature01808)
- Josephs KA, Duffy JR, Strand EA, Whitwell JL, Layton KF, Parisi JE, ...Petersen RC (2006). Clinicopathological and imaging correlates of progressive aphasia and apraxia of speech. *Brain*, 129, 1385–1398. doi:[10.1093/brain/awl078](https://doi.org/10.1093/brain/awl078)
- Jovicich J, Czanner S, Greve D, Haley E, van der Kouwe A, Gollub R, ... Dale A. (2006). Reliability in multi-site structural MRI studies: effects of gradient non-linearity correction on phantom and human data. *Neuroimage*, 30, 436–443. doi:[10.1016/j.neuroimage.2005.09.046](https://doi.org/10.1016/j.neuroimage.2005.09.046)
- Kertesz A, McMonagle P, Blair M, Davidson W, & Munoz DG (2005). The evolution and pathology of frontotemporal dementia. *Brain*, 128, 1996–2005. doi:[10.1093/brain/awh598](https://doi.org/10.1093/brain/awh598)
- Kringelbach ML (2005). The human orbitofrontal cortex: linking reward to hedonic experience. *Nature Reviews Neuroscience*, 6, 691–702. doi:[10.1038/nrn1747](https://doi.org/10.1038/nrn1747)
- Kuperberg GR, Broome MR, McGuire PK, David AS, Eddy M, Ozawa J, ... Fischl B. (2003). Regionally localized thinning of the cerebral cortex in schizophrenia. *Archives of General Psychiatry*, 60, 878–888. doi:[10.1001/archpsyc.60.9.878](https://doi.org/10.1001/archpsyc.60.9.878)
- Kurth F, Zilles K, Fox PT, Laird AR, & Eickhoff SB (2010). A link between the systems: functional differentiation and intergration within the human insula revealed by metaanalysis. *Brain Structure and Function*, 214, 5–6. doi:[10.1007/s00429-010-255-z](https://doi.org/10.1007/s00429-010-255-z)
- Levenson RW (1994). Emotional control: variation and consequences. In Ekman P. & Davidson RJ (Eds.), *The nature of emotion* (pp. 273–279). New York: Oxford University Press.
- Levenson RW (2007). Emotion elicitation with neurological patients. In Coan JA & Allen JJB (Eds.), *The handbook of emotion elicitation and assessment* (pp. 158–168). New York: Oxford University Press.
- Levenson RW, Sturm VE, & Haase CM (2014). Emotional and behavioral symptoms in neurodegenerative disease: A model for studying the neural bases of psychopathology. *Annual Review of Clinical Psychology*, 10, 581–606. doi:[10.1146/annurev-clinpsy-032813-153653](https://doi.org/10.1146/annurev-clinpsy-032813-153653)
- Manoochchri M, & Huey ED (2012). Diagnosis and management of behavioral issues in frontotemporal dementia. *Current Neurology and Neuroscience Reports*, 12, 528–536. doi:[10.1007/s11910-012-0302-7](https://doi.org/10.1007/s11910-012-0302-7)
- McKhann G, Drachman DA, Folstein MF, Katzman R, Price DL, & Stadlan E. (1984). Clinical diagnosis of Alzheimer's disease: report of the NINCDSADRDA work group under the auspices of the Department of Health and Human Services Task Force on Alzheimer's disease. *Neurology*, 34, 939–944. doi:[10.1212/WNL.34.7.939](https://doi.org/10.1212/WNL.34.7.939)
- Mesulam MM, & Mufson EJ (1982). Insula of the old world monkey. III: Efferent cortical output and comments on function. *Journal of Comparative Neurology*, 212, 38–52. doi:[10.1002/cne.902120104](https://doi.org/10.1002/cne.902120104)
- Miller BL, Chang L, Mena I, Boone K, & Lesser IM (1993). Progressive right frontotemporal degeneration: clinical, neuropsychological and SPECT characteristics. *Dementia*, 4, 204–213.
- Moore SA, Zoellner LA, & Mollenholt N. (2008). Are expressive suppression and cognitive reappraisal associated with stress-related symptoms? *Behaviour Research and Therapy*, 46, 993–1000. doi:[10.1016/j.brat.2008.05.001](https://doi.org/10.1016/j.brat.2008.05.001)
- Morris JC (1993). The clinical dementia rating scale (CDR): current version and scoring rules. *Neurology*, 43, 2412–2414.
- Mutschler I, Wieckhorst B, Kowalevski S, Derix J, Wentlandt J, Schulze-Bonhage A, & Ball T. (2009). Functional organization of the human anterior insular cortex. *Neuroscience Letters*, 457, 66–70. doi:[10.1016/j.neulet.2009.03.101](https://doi.org/10.1016/j.neulet.2009.03.101)
- Neary D, Snowden JS, Gustafson L, Passant U, & Stuss D. (1998). Frontotemporal lobar degeneration: a consensus on clinical diagnostic criteria. *Neurology*, 51, 1546–1554. doi:[10.1212/WNL.51.6.1546](https://doi.org/10.1212/WNL.51.6.1546)

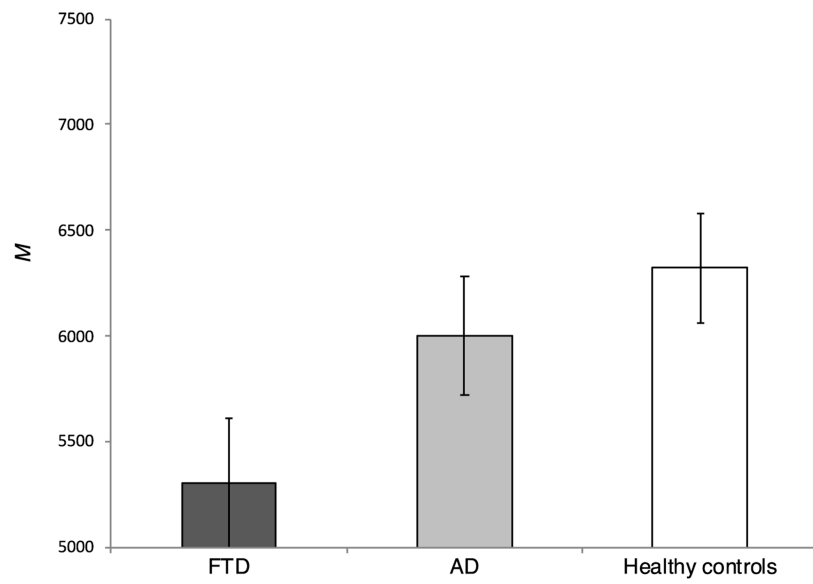
- Nestor PJ, Graham NL, Fryer TD, Williams GB, Patterson K, & Hodges JR (2003). Progressive non-fluent aphasia is associated with hypometabolism centred on the left anterior insula. *Brain*, 126, 2406–2418. doi:[10.1093/brain/awg240](https://doi.org/10.1093/brain/awg240)
- O'Doherty J, Kringelbach ML, Hornak J, Andrews C, & Rolls ET (2001). Abstract reward and punishment representations in the human orbitofrontal cortex. *Nature Neuroscience*, 4, 95–102. doi:[10.1038/82959](https://doi.org/10.1038/82959)
- Öngür D, & Price JL (2000). The organization of networks within the orbital and medial prefrontal cortex of rats, monkeys and humans. *Cerebral Cortex*, 10, 206–219.
- Öngür D, & Price JL (2000). The organization of networks within the orbital and medial prefrontal cortex of rats, monkeys and humans. *Cerebral Cortex*, 10, 206–219. doi:[10.1093/cercor/10.3.206](https://doi.org/10.1093/cercor/10.3.206)
- Paton JJ, Belova MA, Morrison SE, & Salzman CD (2006). The primate amygdala represents the positive and negative value of visual stimuli during learning. *Nature*, 439, 865–870. doi:[10.1038/nature04490](https://doi.org/10.1038/nature04490)
- Pereira JM, Williams GB, Acosta-Cabrero J, Pengas G, Spillantini MG, Xuereb JH, ... Nestor PJ (2009). Atrophy patterns in histologic vs clinical groupings of frontotemporal lobar degeneration. *Neurology*, 72, 1653–1660. doi:[10.1212/WNL.0b013e3181a55fa2](https://doi.org/10.1212/WNL.0b013e3181a55fa2)
- Phillips ML, Drevets WC, Rauch SL, & Lane R. (2003). Neurobiology of emotion perception I: the neural basis of normal emotion perception. *Biological Psychiatry*, 54, 504–514. doi:[10.1016/S0006-3223\(03\)00168-9](https://doi.org/10.1016/S0006-3223(03)00168-9)
- Rascovsky K, Hodges JR, Knopman D, Mendez MF, Kramer JH, Neuhaus J, ... Miller BL (2011). Sensitivity of revised diagnostic criteria for the behavioural variant of frontotemporal dementia. *Brain*, 134, 2456–2477. doi:[10.1093/brain/awr179](https://doi.org/10.1093/brain/awr179)
- Reynolds SM, & Zahm DS (2005). Specificity in the projections of prefrontal and insular cortex to ventral striatopallidum and the extended amygdala. *Journal of Neuroscience*, 25, 11757–11767. doi:[10.1523/JNEUROSCI.3432-05.2005](https://doi.org/10.1523/JNEUROSCI.3432-05.2005)
- Robinson TE, & Berridge KC (2008). The incentive sensitization theory of addiction: some current issues. *Philosophical Transactions of the Royal Society of London. Series B, Biological Sciences*, 363, 3131–3146. doi:[10.1098/rstb.2008.0093](https://doi.org/10.1098/rstb.2008.0093)
- Rohrer JD, Warren JD, Modat M, Ridgway GR, Douiri A, Rossor MN, ... Fox NC (2009). Patterns of cortical thinning in the language variants of frontotemporal lobar degeneration. *Neurology*, 72, 1562–1569. doi:[10.1212/WNL.0b013e3181a4124e](https://doi.org/10.1212/WNL.0b013e3181a4124e)
- Rolls ET, & Grabenhorst F. (2008). The orbitofrontal cortex and beyond: from affect to decision-making. *Progress in Neurobiology*, 86, 216–244. doi:[10.1016/j.pneurobio.2008.09.001](https://doi.org/10.1016/j.pneurobio.2008.09.001)
- Rosas HD, Liu AK, Hersch S, Glessner M, Ferrante RJ, Salat DH, ... Fischl B. (2002). Regional and progressive thinning of the cortical ribbon in Huntington's disease. *Neurology*, 58, 695–101. doi:[10.1212/WNL.58.5.695](https://doi.org/10.1212/WNL.58.5.695)
- Rosen HJ, Gorno-Tempini ML, Goldman WP, Perry RJ, & Schuff N. (2002). Patterns of brain atrophy in frontotemporal dementia and semantic dementia. *Neurology*, 58, 198–208. doi:[10.1212/WNL.58.2.198](https://doi.org/10.1212/WNL.58.2.198)
- Rozin P, Haidt J, & McCauley CR (2008). Disgust. In Lewis M. & Haviland JM (Eds.), *Handbook of emotions* (pp. 631–653). New York, NY : Guilford Press.
- Rushworth MF, & Behrens TE (2008). Choice, uncertainty and value in prefrontal and cingulate cortex. *Nature Neuroscience*, 11, 389–391. doi:[10.1038/nn2066](https://doi.org/10.1038/nn2066)
- Salat DH, Buckner RL, Snyder AZ, Greve DN, Desikan RS, Busa E, ... Fischl B. (2004). Thinning of the cerebral cortex in aging. *Cerebral Cortex*, 14, 121–130. doi:[10.1093/cercor/bhh032](https://doi.org/10.1093/cercor/bhh032)
- Saper CB (2002). The central autonomic nervous system: conscious visceral perception and autonomic pattern generation. *Annual Review of Neuroscience*, 25, 433–469. doi:[10.1146/annurev.neuro.25.032502.111311](https://doi.org/10.1146/annurev.neuro.25.032502.111311)
- Schoenbaum G, Roesch MR, & Stalnaker TA (2006). Orbitofrontal cortex, decision-making and drug addiction. *Trends in Neuroscience*, 29, 116–124. doi:[10.1016/j.tins.2005.12.006](https://doi.org/10.1016/j.tins.2005.12.006)
- Schoenbaum G, Setlow B, Saddoris MP, & Gallagher M. (2003). Encoding predicted outcome and acquired value in orbitofrontal cortex during cue sampling depends upon input from basolateral amygdala. *Neuron*, 39, 855–867. doi:[10.1016/S0896-6273\(03\)00474-4](https://doi.org/10.1016/S0896-6273(03)00474-4)

- Seeley WW (2008). Selective functional, regional, and neuronal vulnerability in frontotemporal dementia. *Current Opinion in Neurology*, 21, 701–707. doi:[10.1097/WC0.0b013e3283168e2d](https://doi.org/10.1097/WC0.0b013e3283168e2d)
- Seeley WW (2010). Anterior insula degeneration in frontotemporal dementia. *Brain Structure and Function*, 214, 465–475. doi:[10.1007/s00429-010-0263-z](https://doi.org/10.1007/s00429-010-0263-z)
- Seeley WW, Bauer AM, Miller BL, Gorno-Tempini ML, Kramer JH, Weiner M, & Rosen HJ (2005). The natural history of temporal variant frontotemporal dementia. *Neurology*, 64, 1384–1390.
- Seeley WW, Crawford RK, Zhou J, Miller BL, & Greicius MD (2009). Neurodegenerative diseases target largescale human brain networks. *Neuron*, 62, 42–52. doi :[10.1016/j.neuron.2009.03.024](https://doi.org/10.1016/j.neuron.2009.03.024)
- Seeley WW, Menon V, Schatzberg AF, Keller J, Glover GH, Kenna H, ... Greicius MD (2007). Dissociable intrinsic connectivity networks for salience processing and executive control. *The Journal of Neuroscience*, 27, 2349–2356. doi:[10.1523/JNEUROSCI.5587-06.2007](https://doi.org/10.1523/JNEUROSCI.5587-06.2007)
- Segonne F, Dale AM, Busa E, Glessner M, Salat D, Hahn HK, & Fischl B. (2004). A hybrid approach to the skull stripping problem in MRI. *Neuroimage*, 22, 1060–1075. doi:[10.1016/j.neuroimage.2004.03.032](https://doi.org/10.1016/j.neuroimage.2004.03.032)
- Segonne F, Pacheco J, & Fischl B. (2007). Geometrically accurate topology-correction of cortical surfaces using nonseparating loops. *IEEE Transactions of Medical Imaging*, 26, 518–529. doi: [10.1109/TMI.2006.887364](https://doi.org/10.1109/TMI.2006.887364)
- Seider BH, Shiota MN, Whalen P, & Levenson RW (2011). Greater sadness reactivity in late life. *Social Cognitive and Affective Neuroscience*, 6, 186–194. doi:[10.1093/scan/nsq069](https://doi.org/10.1093/scan/nsq069)
- Shiota MN, & Levenson RW (2012). Turn down the volume or change the channel? Emotion effects of detached versus positive reappraisal. *Journal of Personality and Social Psychology*, 103, 416–429. doi:[10.1037/a0029208](https://doi.org/10.1037/a0029208)
- Simmons WK, Avery JA, Barcalow JC, Bodurka J, Drevets WC, & Patrick B. (2013). Keeping the body in mind: insula functional organization and functional connectivity integrate interoceptive, exteroceptive, and emotional awareness. *Human Brain Mapping*, 34, 2944–2958. doi:[10.1002/hbm.22113](https://doi.org/10.1002/hbm.22113)
- Simpson J, Carter S, Anthony SH, & Overton PG (2006). Is disgust a homogenous emotion? *Motivation and Emotion*, 30, 31–41. doi:[10.1007/s11031-006-9005-1](https://doi.org/10.1007/s11031-006-9005-1)
- Singer T, Critchley HD, & Preuschoff K. (2009). A common role of insula in feelings, empathy, and uncertainty. *Trends in Cognitive Sciences*, 13, 334–340. doi:[10.1016/j.tics.2009.05.001](https://doi.org/10.1016/j.tics.2009.05.001)
- Sled JG, Zijdenbos AP, & Evans AC (1998). A nonparametric method for automatic correction of intensity nonuniformity in MRI data. *IEEE Transactions on Medical Imaging*, 17, 87–97. doi: [10.1109/42.668698](https://doi.org/10.1109/42.668698)
- Snowden JS, Bathgate D, Varma A, Blackshaw A, Gibbons ZC, & Neary D. (2001). Distinct behavioural profiles in frontotemporal dementia and semantic dementia. *Journal of Neurology, Neurosurgery, and Psychiatry*, 70, 323–332. doi:[10.1136/jnnp.70.3.323](https://doi.org/10.1136/jnnp.70.3.323)
- Stein M, Simmons AN, Feinstein JS, & Paulus MP (2007). Increased amygdala and insula activation during emotion processing in anxiety-prone subjects. *American Journal of Psychiatry*, 164, 318–327. doi:[10.1176/appi.ajp.164.2.318](https://doi.org/10.1176/appi.ajp.164.2.318)
- Sturm VE, Sollberger M, Seeley WW, Rankin KP, Ascher EA, Rosen HJ, ... Levenson RW (2013). Role of right pregenual anterior cingulate cortex in self-conscious emotion reactivity. *Social Cognitive and Affective Neuroscience*, 8, 468–474. doi:[10.1093/scan/nss023](https://doi.org/10.1093/scan/nss023)
- Verstaen A, Eckart JA, Muhtadie L, Otero MC, Sturm VE, Haase CM, ...Levenson RW (2016). Insular atrophy and diminished disgust reactivity. *Emotion*. doi:[10.1037/emo0000195](https://doi.org/10.1037/emo0000195)
- Wright P, He G, Shapira NA, Goodman WK, & Liu Y. (2004). Disgust and the insula: fMRI responses to pictures of mutilation and contamination. *NeuroReport*, 15, 2347–2351. doi: [10.1097/00001756-200410250-00009](https://doi.org/10.1097/00001756-200410250-00009)

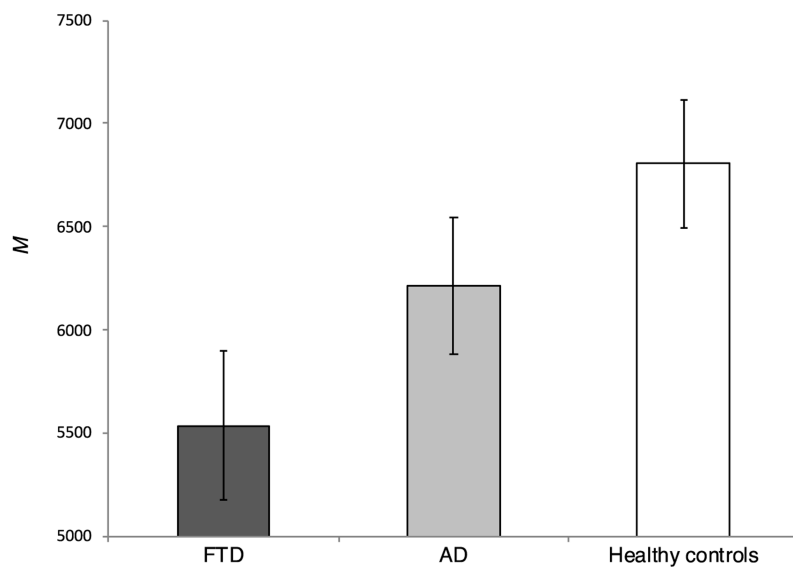


**Figure 1.** Total emotional behavior during the suppression trial for FTD patients, AD patients, and health controls. *Note.* Scores adjusted for age, gender, and emotional behaviors during the reactivity trial. Horizontal bars represent estimated marginal means. Error bars represent the standard error of the mean. \*\*  $p < .01$

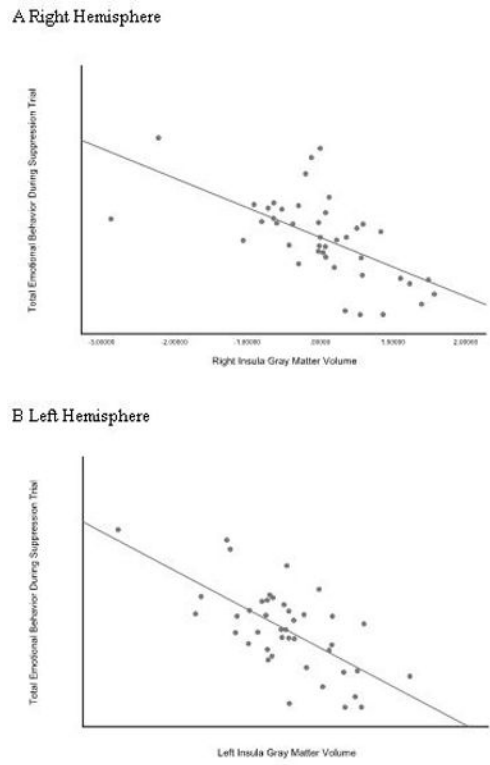
A. Right Insula Gray Matter Volume



B Left Insula Gray Matter Volume



**Figure 2.** Right (Panel A) and left (Panel B) Insula Gray Matter Volumes Among Patients with FTD, Patients with AD, and Healthy Controls *Note.* Scores adjusted for age, gender, emotional behavior during the reactivity trial, ICV, scanner type, and FreeSurfer version. Horizontal bars represent estimated marginal means. Error bars represent the standard error of the mean.



**Figure 3.** Insula gray matter volumes and total emotional behavior during the suppression trial. *Note.* Panel A: Right hemisphere. Panel B: Left hemisphere. Scores adjusted for age, gender, emotional behavior during the reactivity trial, ICV, scanner type, FreeSurfer version, and diagnosis. Each data point represents data from one study participant.

**Table 1.**

Demographic, Clinical, and Emotional Characteristics of FTD Patients, AD Patients, and Healthy Controls

	FTD Patients	AD Patients	Controls	Group Difference
<i>N</i> Full Sample Imaging Only	59 <i>11</i>	52 <i>11</i>	38 <i>20</i>	$\chi^2(2)=4.60, p=.100$ $\chi^2(2)=3.86, p=.145$
Demographic Characteristics, <i>M</i> ( <i>SD</i> )				
Age (years)	62.26 (7.57) <i>64.71 (6.13)</i>	62.60 (8.59) <i>59.89 (7.02)</i>	64.94 (11.91) <i>62.59 (13.59)</i>	$F(2,146)=1.08, p=.342$ $F(2,39)=.57, p=.569$
Gender (% female)	33.9 <i>18.2</i>	38.5 <i>36.4</i>	55.3 <i>65.0</i>	$\chi^2(2)=4.57, p=.102$ $\chi^2(2)=6.75, p=.034$
Education (in years)	16.34 (2.64) <i>15.91 (3.18)</i>	15.88 (3.14) <i>15.55 (4.70)</i>	17.52 (2.18) <i>17.70 (2.00)</i>	$F(2,135)=3.30, p=.040$ $F(2,39)=2.03, p=.144$
Race (% White)	89.7 <i>100</i>	94.2 <i>90.9</i>	92.1 <i>100</i>	$\chi^2(2)=77, p=.679$ $\chi^2(2)=2.80, p=.247$
Clinical Characteristics, <i>M</i> ( <i>SD</i> )				
CDR	.93 (.61) <i>.77 (.52)</i>	.64 (1.27) <i>.94 (.46)</i>	.04 (.14) <i>.05 (.15)</i>	$F(2,115)=5.10, p=.008$ $F(2,28)=2.37, p=.000$
Total Emotional Behavior				
Reactivity Trial	24.05(18.77) <i>24.45(14.98)</i>	24.71(15.84) <i>25.73(12.85)</i>	34(17.53) <i>28.25(16.46)</i>	$F(2,146)=4.33, p=.015$ $F(2,39)=.25, p=.784$
Suppression Trial	13.81(14.70) <i>18.00(19.27)</i>	12.02(15.60) <i>17.36(18.57)</i>	9.79(13.61) <i>6.90(10.31)</i>	$F(2,146)=86, p=.424$ $F(2,39)=2.59, p=.088$

Note. *M* and *SD* for neuroimaging sample in italics. FTD = Frontotemporal dementia. AD = Alzheimer's disease. CDR = Clinical Dementia Rating Scale.

**Table 2.**

Brain Regions Volumes Significantly Associated with Emotion Suppression Behavior in FTD Patients, AD Patients, and Healthy Controls

	FTD patients		AD patients		Healthy controls	
	<i>M</i>	<i>SD</i>	<i>M</i>	<i>SD</i>	<i>M</i>	<i>SD</i>
<b>Left hemisphere</b>						
Insula	5494.55	901.983	5972.00	1279.284	6233.65	686.667
Fusiform gyrus	8249.91	1594.356	7744.18	1502.298	9364.30	1558.762
Inferior temporal gyrus	8752.55	1959.332	9149.00	1743.030	10464.95	1954.854
Isthmus of the cingulate gyrus	2124.55	424.251	1770.55	397.351	2260.15	479.710
Lateral orbitofrontal cortex	6689.73	1542.580	7028.27	1573.496	7436.30	1193.352
Medial orbitofrontal cortex	3905.55	641.342	3904.00	785.175	4185.15	787.470
Middle temporal gyrus	9004.00	1797.834	9098.64	2115.158	10607.10	1752.427
Paracentral lobule	3305.09	579.259	3052.64	486.790	3507.65	656.791
Pars triangularis	3174.09	578.453	3057.91	667.734	3755.75	872.518
Superior frontal gyrus	19602.27	3330.848	19291.27	3060.141	22849.40	3956.731
Supraorbital margin	9537.18	1530.481	10548.64	1714.410	12294.65	2282.338
Superior temporal gyrus	9522.55	1511.747	8192.00	1674.468	10746.35	2072.821
Temporal pole	1474.36	558.589	1961.64	403.226	2350.65	358.891
<b>Right hemisphere</b>						
Insula	5268.73	942.181	5757.45	959.200	5846.40	656.618
Inferior parietal cortex	13014.36	2194.804	11645.18	2199.619	14266.05	2595.935
Lateral orbitofrontal cortex	6424.55	1386.668	6926.73	1404.789	7062.80	1199.590
Medial orbitofrontal cortex	4301.55	851.175	4361.09	1004.128	4580.75	801.181
Posterior cingulate Cortex	2962.36	513.751	3196.09	771.121	3265.25	648.063
Rostral middle frontal gyrus	15519.09	2432.576	13973.36	3620.321	15666.80	2869.624

*Note.* Mean gray matter volumes (in cubic millimeters) and SD's for brain regions that were associated with total emotional behavior during the suppression trial in the partial correlation analyses ( $r_p > 0.5$ ). FTD = Frontotemporal dementia. AD = Alzheimer's disease.